

# **Geo Tag Pictures of the High End Equipment**

# **CBCT (Cone Beam Computed Tomogram)**

## 1.CBCT (Cone Beam Computed Tomogram)




Fig 1 CBCT installed in Department of Oral Medicine and Radiology



*Subramanya Sharma*  
Principal  
Army College of Dental Sciences




Fig 2 Patient undergoing the CBCT Scan

*Sharma*  
(Dr. S. Subramanya Sharma)  
Principal  
Army College of Dental Sciences



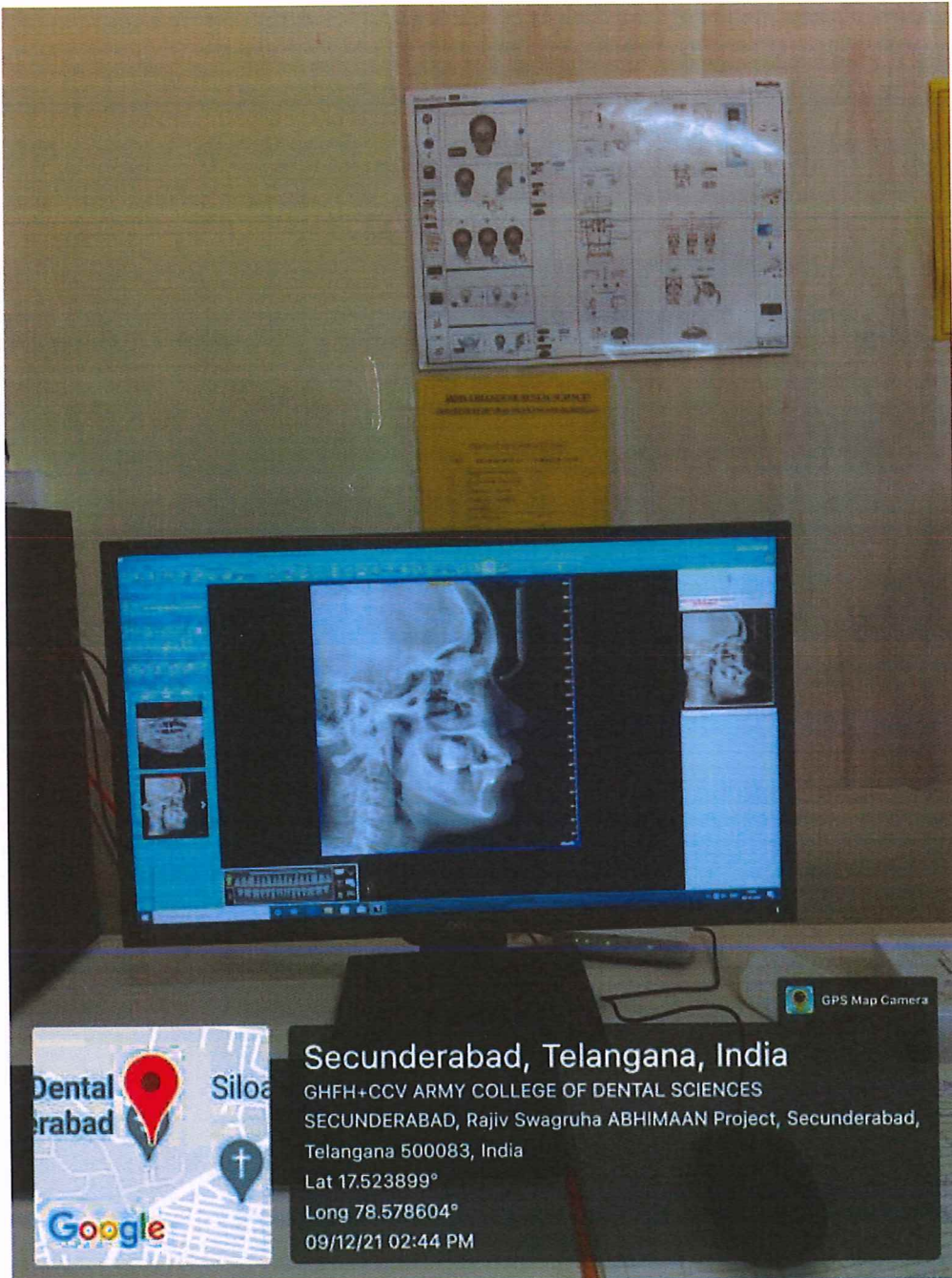


Fig 3 CBCT interpretation in digital form on Computers

*Sharma*  
(Dr. S Subramanya Sharma)  
Principal  
Army College of Dental Sciences



# **Imaging and Morphometric Software**

## 2.Imaging and Morphometric Software

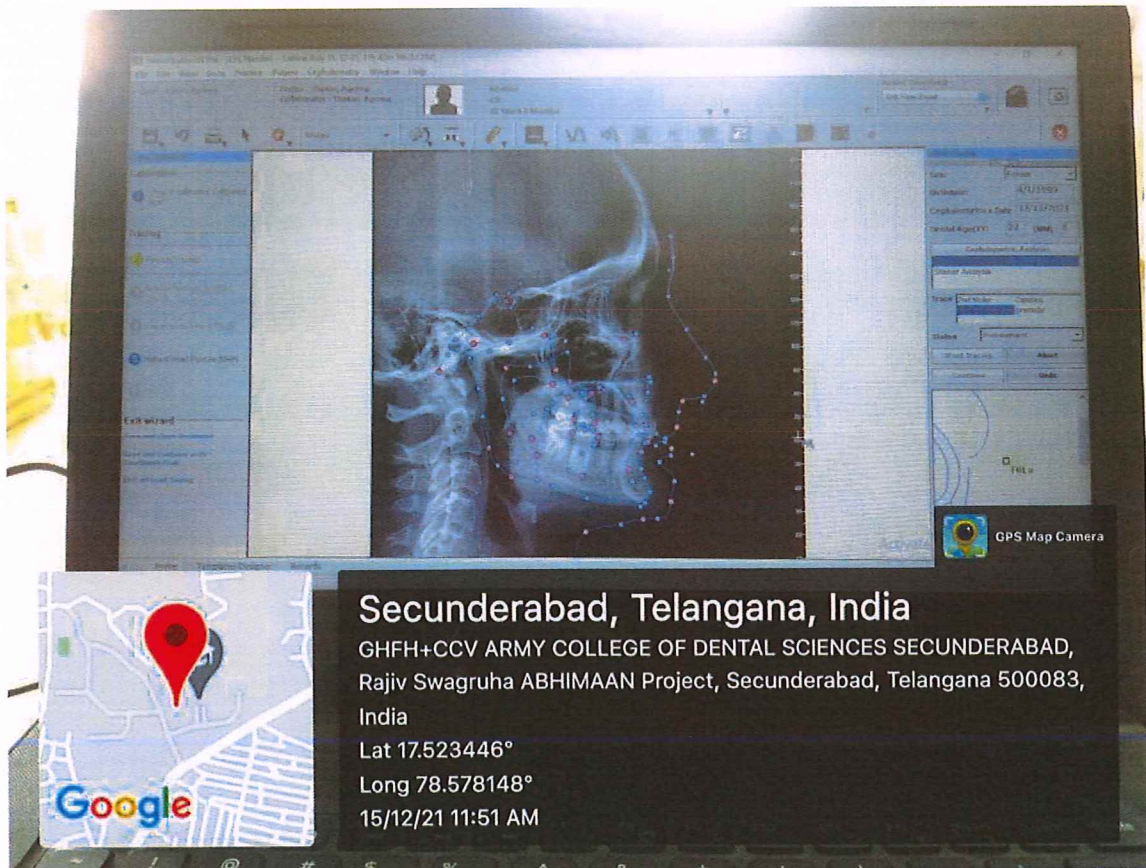



Fig 4 Imaging and Morphometric Software in department of Orthodontics being used for treatment planning of the Patient.

  
(Dr. S Subramanya Sharma)  
Principal  
Army College of Dental Sciences



# **Endodontic Microscope**



### 3. Endodontic Microscope

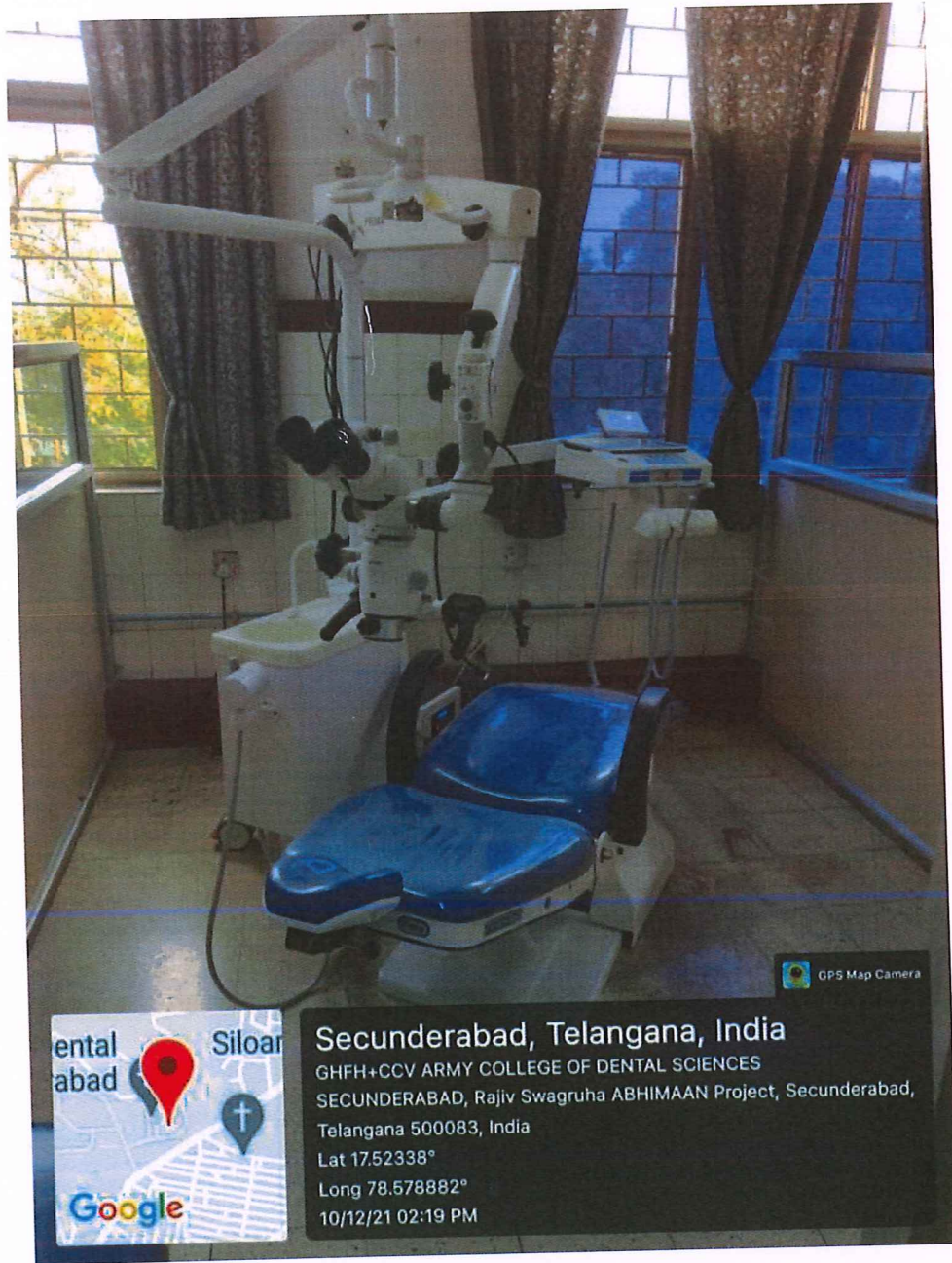



Fig 5 Operating Microscope in Department of Conservative Dentistry and Endodontics

*(Dr. S Subramanya Sharma)*  
Principal  
Army College of Dental Sciences



# **Dental Laser Unit**

#### 4.Dental Laser Unit

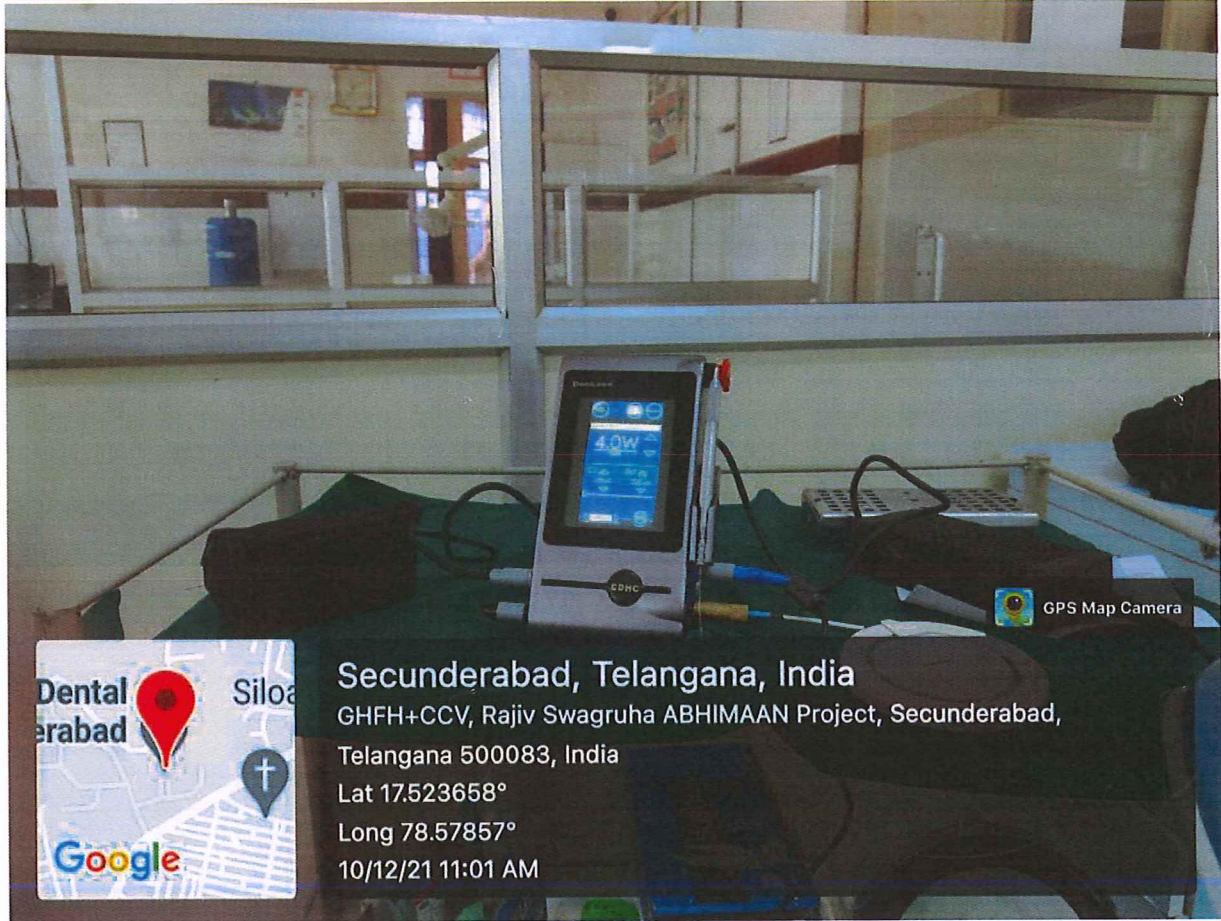



Fig 6 Soft tissue Laser in Department of Periodontics

  
(Dr. S. Subramanya Sharma)  
Principal  
Army College of Dental Sciences



# **Light Based Microscopy (phase contrast microscopy)**

## 5. LIGHT BASED MICROSCOPY (PHASE CONTRAST MICROSCOPY)




Fig 7 Trinocular microscope in Department of Oral Pathology being used by the student to view the tissues slides

*Sharma*  
Dr. S Subramanya Sharma)  
Principal  
Army College of Dental Sciences






Fig 7 Trinocular microscope in Department of Oral Pathology being used by the student view the tissues slides



*[Handwritten signature]*

*[Handwritten signature]*  
Principal  
(Dr. S Subramanya Sharma)  
Principal  
Army College of Dental Sciences